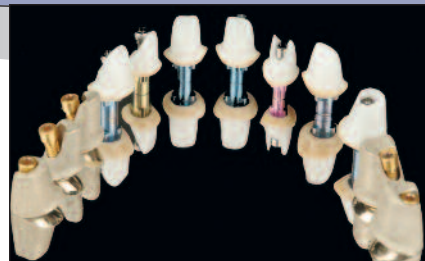

# COMPREHENSIVE ESTHETIC AND FUNCTIONAL REHABILITATION WITH A CAD/CAM ALL-CERAMIC SYSTEM



Iñaki Gamborena, DMD, MSD, FID<sup>1</sup>  
Markus B. Blatz, DMD, PhD<sup>2</sup>

CAD/CAM technology and all-ceramic systems have become integral parts of modern dentistry and laboratory technology. The Procera system<sup>1</sup> (Nobel Biocare, Göteborg, Sweden) was introduced over a decade ago and offers various components, materials, and techniques within one concept (C&B&I: crown & bridge & implant, Nobel Biocare). The CAD/CAM system allows fabrication of single- and multiple-unit frameworks as well as implant components (Procera Crown, Procera Bridge, Procera Abut-

ment). Each of these restorative components can be fabricated from titanium alloy, densely sintered aluminum oxide ceramic (Alumina), or densely sintered zirconium oxide ceramic (Zirconia).

The advantages, properties, and clinical applications of the all-ceramic components and materials used with the Procera system, based on scientific evidence, are discussed in this article. The featured case presentation, a comprehensive full-mouth rehabilitation, demonstrates the versatility and esthetic capabilities of the Procera system.

## ALUMINUM OXIDE CERAMICS

High-strength ceramic materials (eg, aluminum oxide and zirconium oxide) are typically used as coping materials for full-coverage restorations and fixed partial denture frameworks.<sup>2-5</sup> CAD/CAM technology compensates for the significant shrinkage of metal oxide high-strength ceramic materials during sintering. An industrialized production pro-

<sup>1</sup>Affiliate Associate Professor, University of Washington School of Dentistry, Seattle, Washington, USA; private practice, San Sebastian, Spain.

<sup>2</sup>Professor of Restorative Dentistry and Chairman, Department of Preventive and Restorative Sciences, University of Pennsylvania School of Dental Medicine, Philadelphia, Pennsylvania, USA.

**Correspondence to:** Dr Iñaki Gamborena, Resurreccion M<sup>a</sup> De Azkue, 6, 20018 San Sebastian, Spain.  
E-mail: gambomila@arrakis.es

cess bears multiple advantages in respect to the unique sintering temperatures and conditions of high-strength ceramics and outsourcing of a critical laboratory procedure. Procera uses densely sintered, high-purity aluminum oxide (>99.9%) ceramics, which offer a flexural strength of 610 MPa.<sup>6</sup> Procera Alumina has a higher degree of translucency compared to Procera Zirconia and may, therefore, be preferred in anterior, low-pressure-bearing areas of esthetic significance.<sup>4,5</sup> Alumina is used for single crowns, implant abutments, and laminate veneers.<sup>2</sup> The clinical long-term success of Procera Alumina crowns has been validated in many clinical studies.<sup>7-9</sup> Most recently, Galindo et al<sup>10</sup> reported on the follow-up of 39 patients with 135 Procera Alumina crowns. The cumulative survival rate was 99% after 5 and 7 years.

## ZIRCONIUM OXIDE CERAMICS

Zirconium oxide ceramics provide superior physical properties (high flexural strength), biocompatibility, and excellent esthetics.<sup>4,5</sup> The inherent strength of zirconia makes it useful in a variety of clinical applications including full-coverage crowns, resin-bonded fixed and conventional fixed partial dentures, implant abutments, and even long-span implant bars.<sup>11,12</sup> Lifetime predictions reveal favorable success rates for zirconium oxide ceramic restorations.<sup>13</sup> In dentistry, zirconium oxide (ZrO<sub>2</sub>) ceramic is mostly used in a tetragonal crystalline phase, partially stabilized with yttrium oxide. Polycrystalline zirconium oxide ceramics provide a flexural strength greater than 1,000 MPa and feature a unique material property: active crack resistance. External forces transfer the partially stabilized tetragonal particle into a monoclinic form. The newly acquired monoclinic form has an increased volume, which gives the material the ability to close a crack (transformation toughening).<sup>4,5</sup>

## VENEERING CERAMICS FOR HIGH-STRENGTH CERAMIC COPINGS

High-strength ceramic copings are veneered with feldspathic (or silica-based) ceramics, which have a low flexural strength but offer superior esthetics and high translucency.<sup>2,3</sup> Feldspathic veneering ceramics for metal-alloy copings typically fail to provide long-term bonds and adequate physical properties when fired to high-strength ceramics due to a mismatch in the thermal coefficient of expansion, weak ceramic-ceramic bonds, and low fracture strength. Aboushelib et al<sup>14</sup> summarized in an in vitro study that cone cracking of the veneering ceramic is the dominant mode of failure of layered all-ceramic restorations. They conclude that higher strength veneering ceramics are needed to exploit the high strength of zirconia. Newer veneering ceramics and bonding methods modified for alumina and zirconia copings provide higher strengths and improved bonding mechanisms that seem to prevent delamination and fractures. Shear bond strengths of three recently developed veneering ceramics to zirconium oxide ceramic were investigated by Blatz et al.<sup>15</sup> Interestingly, all ceramic-ceramic combinations were different from each other but significantly stronger than the metal-ceramic control.

## CEMENTATION

Cementation materials and methods play a critical role in the clinical survival of ceramic restorations.<sup>16-18</sup> Oppes et al<sup>19</sup> conducted an in vitro study on the marginal seal and fracture strength of Procera Alumina crowns after exposure in an artificial chewing simulator. They concluded that the type of luting agent has a significant effect on the fracture strength and microleakage of all-ceramic crowns. Bonding with a composite resin luting agent containing adhesive phosphate monomers

significantly increased the fracture strength and improved the marginal seal of alumina crowns. However, all luting agents used in this investigation provided fracture strengths well above the average physiologic chewing forces. Okutan et al<sup>20</sup> investigated the fracture load and marginal fit of shrinkage-free (ZrSiO<sub>4</sub>) all-ceramic crowns after chewing simulation. In this study, using adhesive composite resin cement resulted in higher mean fracture loads, which were, however, not statistically different from glass-ionomer cement. Even with a reduced coping thickness of 0.4 mm, zirconium oxide ceramic seems to provide adequate strength for nonadhesive cementation.<sup>21</sup>

## CERAMIC IMPLANT ABUTMENTS

Conventional metal abutments may cause gray discoloration of the surrounding gingiva. Aluminum oxide or zirconium oxide ceramic implant abutments prevent this phenomenon.<sup>22</sup> Clinical studies demonstrate that zirconium oxide ceramic abutments had a cumulative survival rate of 100% after 4 and 6 years follow-up.<sup>23,24</sup> While zirconium oxide ceramic offers almost twice the strength, aluminum oxide ceramic abutments feature some esthetic advantages.<sup>25</sup> Att et al<sup>26,27</sup> investigated the strength of Procera zirconia and alumina crowns in combination with titanium, zirconia, and alumina abutments after exposure in an artificial chewing simulator. All material combinations exceeded physiologic chewing forces in the anterior jaw. Fracture strengths of zirconia crowns were significantly different when used with either one of the abutment materials.<sup>26</sup> The combination of zirconia crowns and alumina abutments resulted in the lowest fracture strengths. On the other hand, alumina crowns yield similar strength when used with either zirconia or alumina abutments and were comparable to the zirconia-zirconia combination.<sup>27</sup> Therefore, alumina abutments should preferably be used with alumina

crowns while zirconia abutments can be used with either crown material.

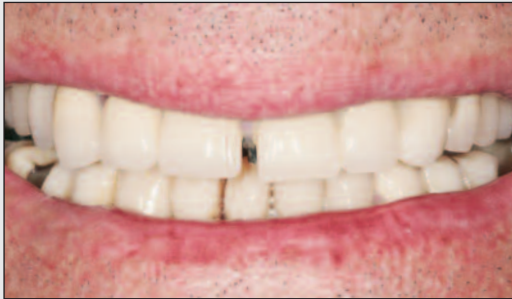## ALL-CERAMIC FIXED PARTIAL DENTURES

Distinctive multidirectional forces and biomechanical requirements in the connector/pontic areas make zirconia the preferred framework material for all-ceramic multiple-unit fixed partial dentures. Studart et al<sup>28</sup> concluded from a recent study that "in spite of the susceptibility to subcritical crack growth, calculations based on the fatigue parameters and on the stress applied on the prosthesis indicate that posterior bridges with zirconia frameworks can exhibit lifetimes longer than 20 years if the diameter of the bridge connector is properly designed." While short-term clinical studies reveal promising success rates, long-term data are still needed to confirm the reliability of zirconia fixed partial dentures.<sup>29</sup>

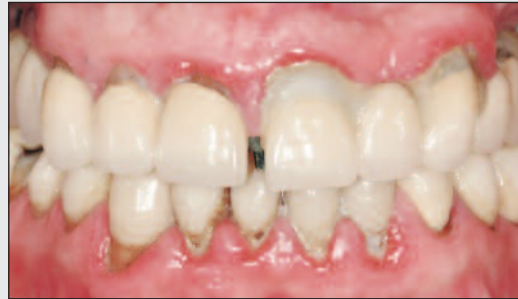## CASE PRESENTATION

A 70-year-old man presented with failing restorations (Figs 1 and 2). The existing full-mouth rehabilitation was less than 2 years old and he complained of difficulty with chewing and function. The initial clinical and radiographic examination revealed heavy horizontal bruxism. The occlusal scheme was locked in position by the existing restorations without anterior or lateral freedom (overjet and immediate anterior disclusion). Reduced opening of the vertical dimension of occlusion contributed to an excessive load to the anterior teeth, which caused the restorations to fracture. The crowns were loose and the abutments were decayed to the gingival margin (Figs 3 and 4). Existing implants (3i Implant Innovations, Palm Beach, FL, USA) in the areas of the maxillary right first premolar to first molar and left first and second molars were well integrated and could be preserved for future restorations. Some mandibular restorations revealed recurrent caries. The periodontal diagnosis included ad-

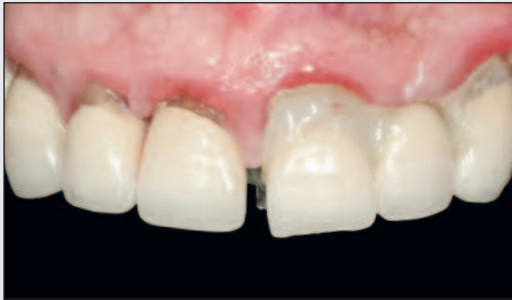## CASE PRESENTATION



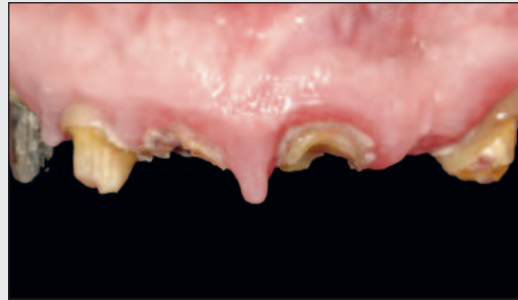1



2



3



4

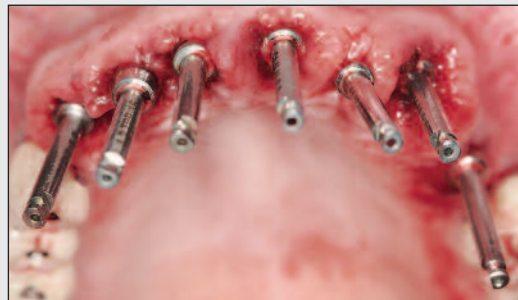**Figs 1 and 2** Failing full-mouth restoration in a 70-year-old patient. Initial clinical situation.

**Figs 3 and 4** Preoperative intraoral frontal view of failing restorations.

**Figs 5 and 6** Dental implants were placed with a flapless surgical procedure immediately after extraction of the destroyed teeth.



5

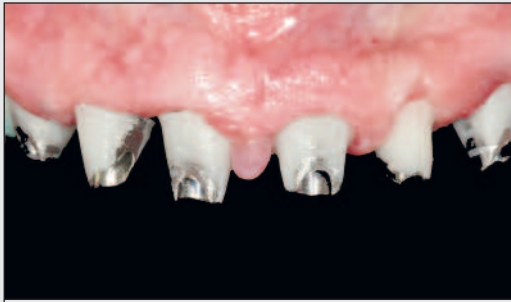

6

vanced generalized gingivitis with localized periodontitis.

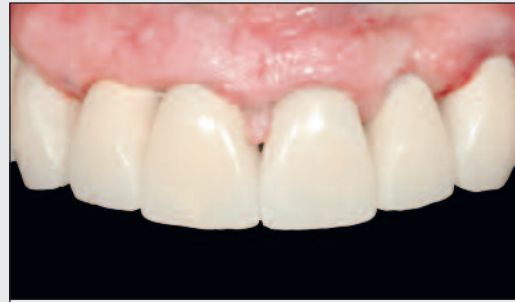The comprehensive restorative treatment plan included implant-supported restorations in the maxilla and tooth-supported restorations in the mandible.

Remaining roots in the maxilla were extracted and immediately replaced with seven implants (Replace Select HA, Nobel Biocare) in a flapless procedure (Figs 5 and 6). Different implant diameters were used to maximize implant-to-bone contact: 5 mm for the central incisors, canines, and left second



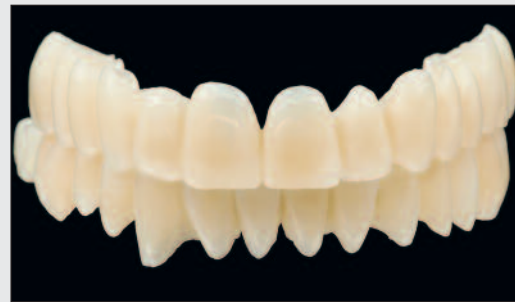7

**Fig 7** Intraoral view of temporary implant abutments customized with light-cure composite.



8

**Fig 8** Full-mouth provisional restorations were placed immediately after insertion of the implants.



9

**Fig 9** After 6 months, new provisional restorations were fabricated in the laboratory to compensate for gingival recession.

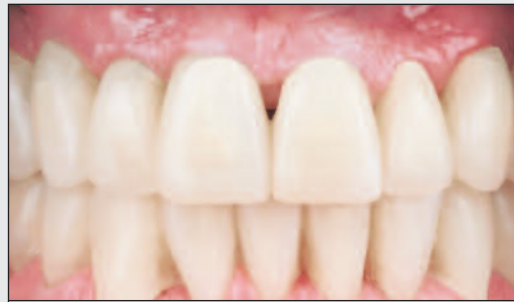molar; 4.3 mm for the right lateral incisor; and 3.5 mm for the left lateral incisor. All implants were planned to be immediately loaded with provisional abutments and fixed full-arch provisional restorations, which were fabricated from the diagnostic waxup. After placement of all implants, temporary abutments (titanium temporary direct abutments, Nobel Biocare) were screwed onto the implants and used as impression copings to transfer the three-dimensional position of the implants to a stone cast. At this stage, the titanium abutments were prepared and the cast was trimmed around each implant to create an emergence profile that matched the contour of the teeth in the diagnostic waxup. Each individual emergence profile was created by applying a light-cure composite resin (Tetric Ceram HB, Ivoclar Vivadent, Schaan, Liechtenstein) into the carved stone and 360 degrees around the implant abutment to create a customized abutment. The composite resin was cured in the laboratory (Triad 2000, Visible Light Cure System, Dentsply/Trubyte, York, PA, USA) and prepared with diamond burs to its ideal abutment form.

The customized provisional abutments (titanium temporary abutments and composite profile) were connected to the implants, and the full-arch shell provisional restoration was relined directly in the patient's mouth. The screw access holes of all abutments were carefully filled with a light-cure temporary material (Fermit, Ivoclar Vivadent). The abutments were isolated with petroleum jelly before relining the provisional restoration with a self-cure acrylic material (Temporary Bridge Resin, Caulk/Dentsply). The provisional restoration was removed after polymerization. Each abutment was unscrewed and the margins were finalized in the laboratory for optimal fit. The abutments were retightened (Fig 7) and the provisional restoration seated to be adjusted to the mandible. In the meantime, the existing mandibular crowns were removed and the abutment teeth were prepared. The mandibular full-arch provisional shell was relined and occlusion adjusted against the maxilla during the same visit. The provisional restorations were cemented with temporary cement (Temp-Bond NE, Kerr, Orange, CA, USA) after final adjustments, recontouring, and polishing (Fig 8).





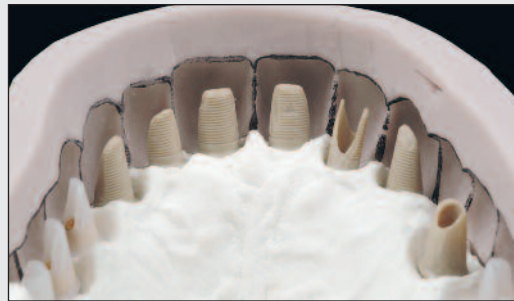10



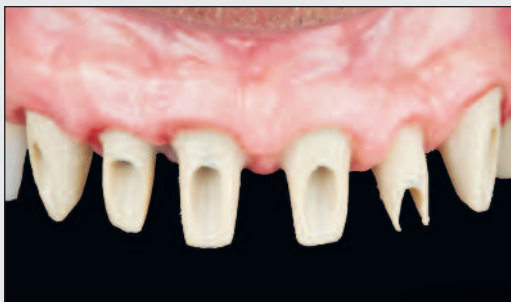11



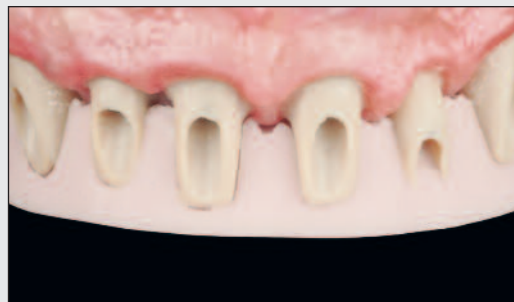12



13



14



15

**Figs 10 and 11** Extraoral and intraoral views of the provisional restorations.

**Figs 12 to 15** Temporary plastic abutments were modified on the cast and tried intraorally for fabrication of customized implant abutments. A silicone index was used to verify optimal contour and position.

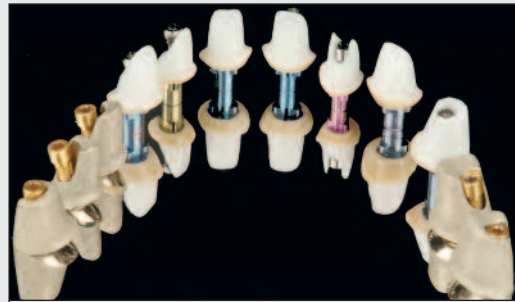Gingival recession of 1 to 2 mm was observed 6 months after tooth extraction and immediate implant placement. The provisional abutments were recontoured and new provisional restorations were fabricated in the laboratory (Fig 9) to compensate for the missing soft tissue. During that period, additional implants were placed to restore both mandibular first molars (5 × 13-mm Straight Replace Select HA, Nobel Biocare). Peri-

odic follow-up visits did not reveal any loosening of the provisional restorations, which demonstrated an adequate occlusal scheme. Optimal functional and esthetic parameters were established during the provisional phase (Figs 10 and 11), which could then be transferred to the final restorations.

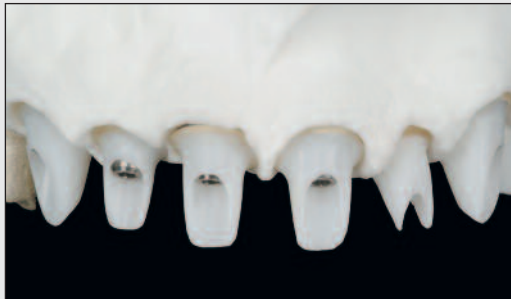Final impressions of the mandible were taken with the double-cord technique (#000 and #0 Ul-

**Fig 16** Definitive implant abutments were fabricated from zirconia (anterior) and gold (posterior).

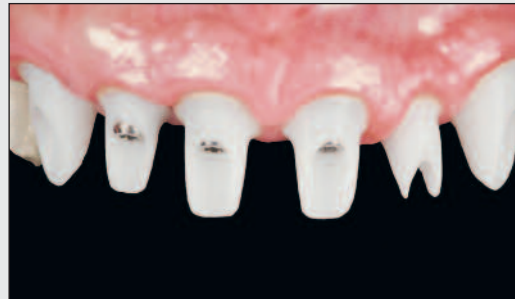**Figs 17 and 18** Optimal contour and adequate tissue support of the implant abutments is verified on the master cast and confirmed intraorally.



16



17



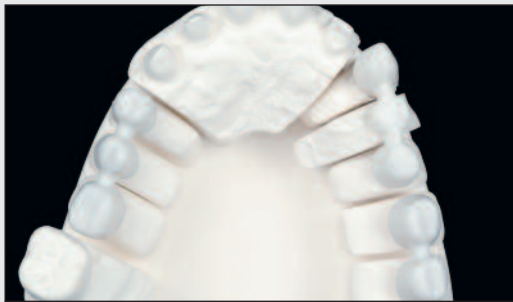18

trapak, Ultradent, South Jordan, UT, USA) and the double-mix impression technique (Virtual VPS putty base regular set and extra-light-body fast set, Ivoclar Vivadent). A pickup impression of the maxillary full-arch provisional restoration was taken with the double-mix technique (Virtual VPS putty base regular set and extra-light-body fast set). The provisional restoration was embedded and locked into the impression material upon removal. The abutments were unscrewed and removed from the mouth, and laboratory implant analogues were connected to the corresponding provisional abutments. The provisional cement was left in place for precise fit and transfer of the tissue topography and implant position to the master cast (GC Fuji-Rock EP Pearl White color, GC, Alsip, IL, USA). Cross-mounted casts were selected to facilitate and transfer the provisional information to the fabrication of the final prosthesis. Acrylic jigs (GC Pattern Resin) were used in addition to interocclusal wax registrations (bite registration wax sheets, Almore International) to maintain the same vertical dimension as established in the provisional restorations.

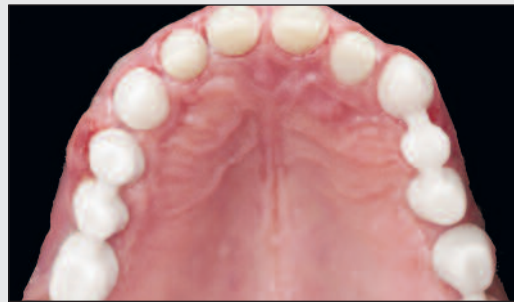Materials for the final restorations were selected at this stage. It was decided to apply all components of the Procera product line, single crowns, implant abutments, and fixed partial dentures, and to take advantage of the unique material properties of zirconia (implant abutments, posterior restorations, and fixed partial dentures) and alumina restorations (anterior crowns). Customized gold abutments were planned for the existing implants in the posterior maxilla.

Two master casts were fabricated from each impression. One was sectioned into individual dies to facilitate scanning of each abutment and pontic site. The second cast was solid and duplicated the provisional restoration for a stable reference of the soft tissue contour and fabrication of zirconia abutments. A silicone index was made from this cast (Zetalabor laboratory high-precision condensation silicone, Zhermack, Badia Polesine, Italy).

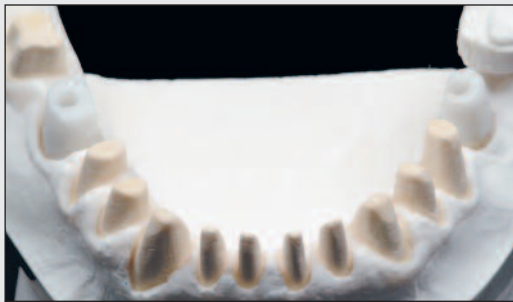The fabrication of a customized zirconia abutment begins with a temporary plastic direct abutment (Nobel Biocare) (Fig 12) that is modified with composite to its ideal contour and form according



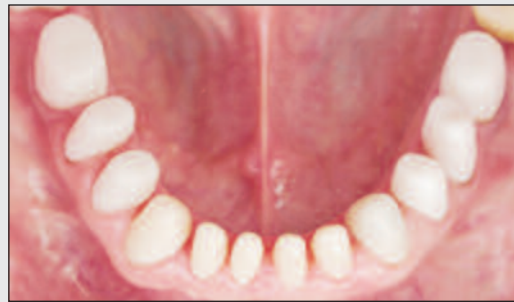19



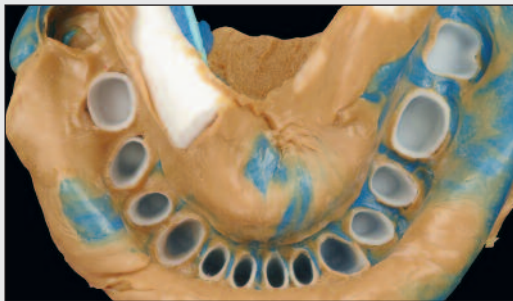
20



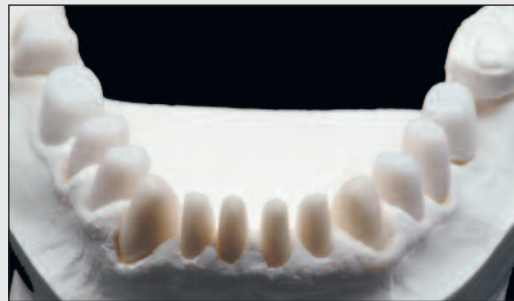21



22



23



24

**Figs 19 to 22** Occlusal views of definitive copings and frameworks on the master casts and during clinical try-in on the prepared teeth and customized abutments. All posterior restorations were made with Procera Zirconia copings. Maxillary incisors and mandibular anterior teeth were restored with Procera Alumina.

**Fig 23** Pickup impression of mandibular copings.

**Fig 24** Solid master cast of the mandibular pickup impression with copings in place.

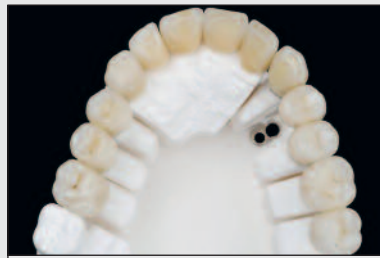to the silicone index made from the provisional restoration (Fig 13). The customized plastic abutments should be tried in the mouth and verified with the silicone index (Figs 14 and 15) before final scanning and fabrication of the definitive implant abutments (Figs 16 to 18). The Procera Forte scanner (Nobel Biocare) was used to scan the multiple-unit restorations, the temporary plastic abutments,

the mandibular preparations, and the pontic ridges as well as the interocclusal records. Material thickness, height, contour, and all other dimensions of the abutments, copings, and frameworks were individually designed on the computer.

All definitive copings and frameworks were tried intraorally to verify fit on the prepared teeth and customized abutments (Figs 19 to 22). Pickup

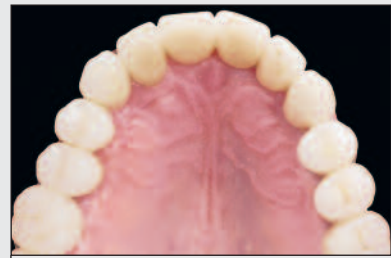

**Fig 25** Definitive maxillary restorations on sectioned master cast.



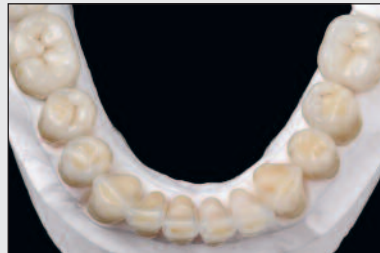25

**Fig 26** Postoperative intraoral occlusal view of maxillary restorations.



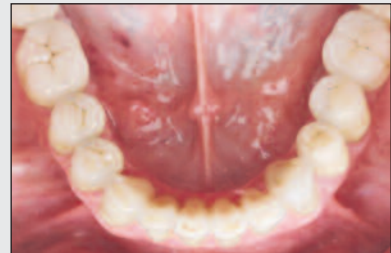26

**Fig 27** Occlusal view of definitive mandibular restorations on the master cast.

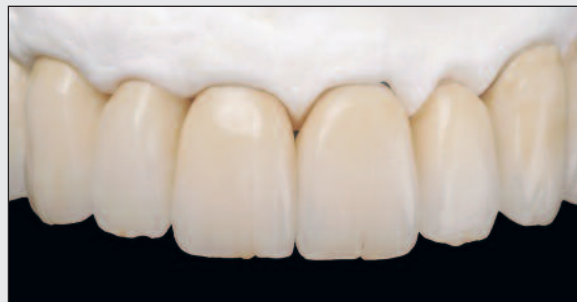

27

**Fig 28** Postoperative intraoral occlusal view of mandibular restorations.

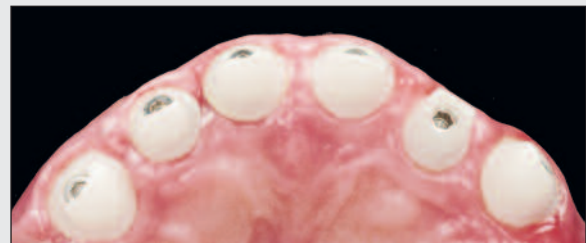

28



29

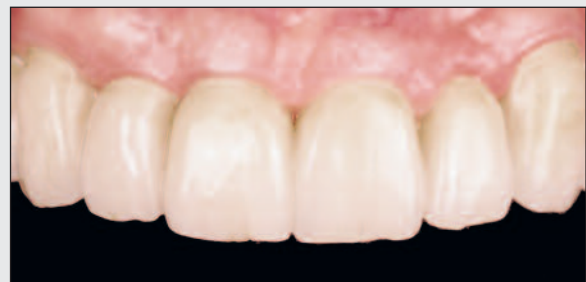**Fig 29** Detailed labial view of maxillary anterior restorations on solid master casts.



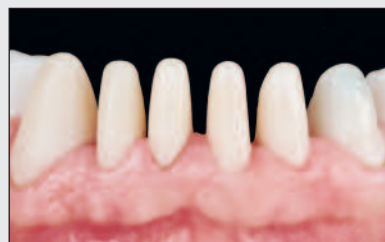30

**Fig 30** Occlusal view of anterior maxillary zirconia abutments.

**Fig 31** Postoperative intraoral labial view of maxillary anterior restorations.

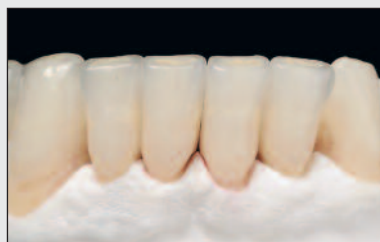

31



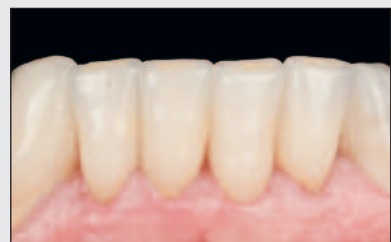32

**Fig 32** Detailed intraoral labial view of mandibular anterior ceramic copings.



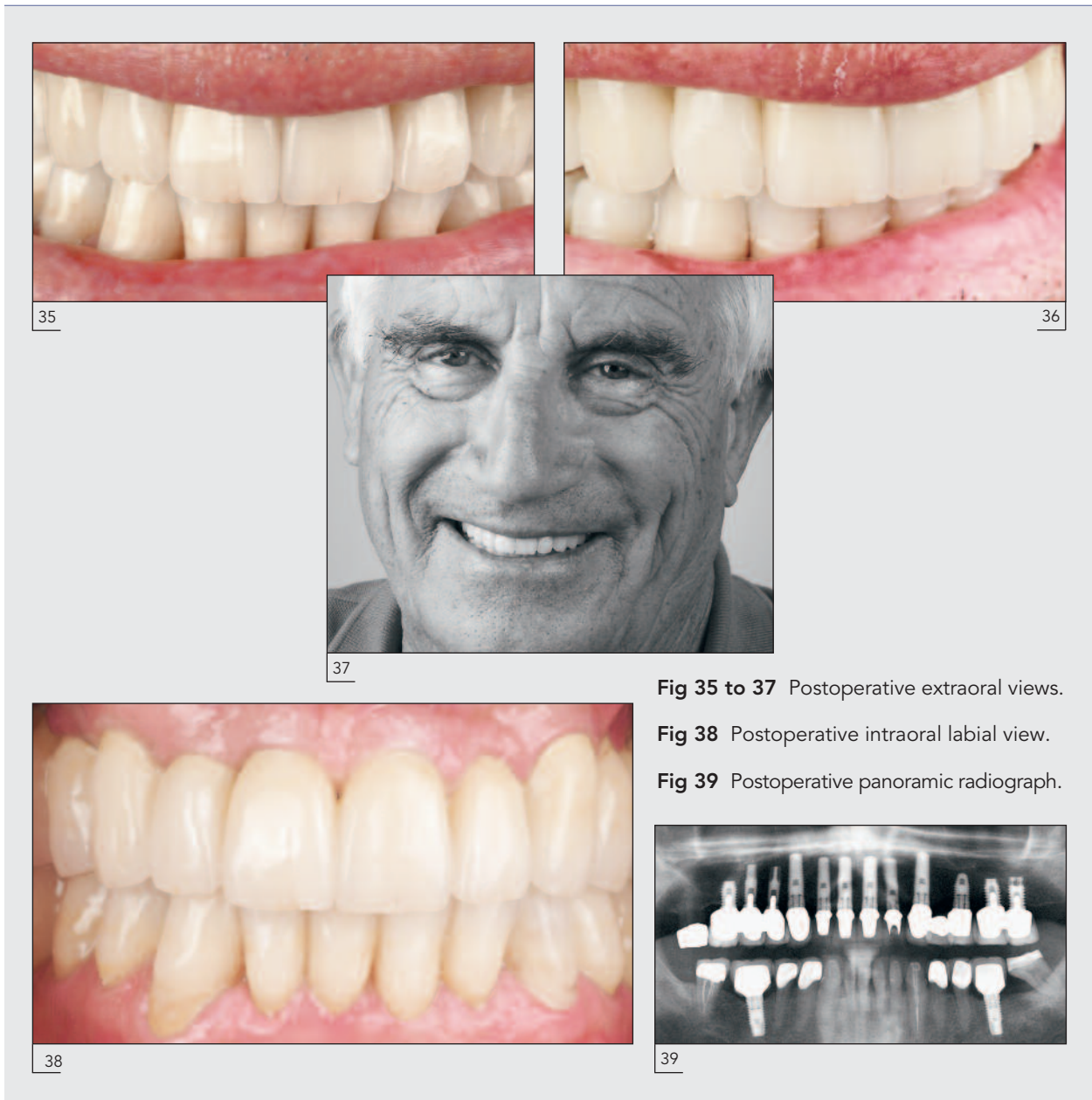
33

**Fig 33** Detailed labial view of mandibular anterior restorations on solid master cast.



34

**Fig 34** Postoperative intraoral labial view of mandibular anterior restorations.



**Fig 35 to 37** Postoperative extraoral views.

**Fig 38** Postoperative intraoral labial view.

**Fig 39** Postoperative panoramic radiograph.

impressions (Virtual VPS) were taken of all copings and frameworks to fabricate solid master casts with an accurate tissue topography (Figs 23 and 24). Sufficient space for the veneering porcelain was verified with silicone indices. The veneering ceramic was applied and the full-mouth restorations were tried in at the bisque-bake stage. The restorations were then finalized, glazed, and stained to create natural esthetics (Figs 25 to 34). The zirconia abutments were

tightened with a torque of 35 Ncm and screw access holes were closed with a light-cure temporary restorative material (Fermit, Ivoclar Vivadent) before final cementation. Adhesive resin (RelyX Unicem Transparent, 3M ESPE, St Paul, MN, USA) was used for definitive insertion of the implant restorations while RelyX luting (3M ESPE) was used for the mandibular natural dentition. Figures 35 to 38 show postoperative views. After definitive insertion, a panoramic radiograph was

taken (Fig 39) and an occlusal splint was delivered to protect the restorations during sleep.

## CONCLUSION

Scientific evidence, physical properties, and the vast clinical possibilities of the Procera CAD/CAM all-ceramic system have been discussed and illustrated in this article. While the existing evidence demonstrates excellent clinical longevity of high-strength all-ceramic restorations, further research will be necessary to fully explore their advantages and to apply them in the most favorable manner.

## ACKNOWLEDGMENTS

The authors thank Dr Pedro Peña for the excellent implant surgery, Mr Iñigo Casares for the design and scanning of the copings and frameworks, and Dale Denny for the beautiful porcelain work featured in the case presentation.

## REFERENCES

- Andersson M, Oden A. A new all-ceramic crown. A dense-sintered, high-purity alumina coping with porcelain. *Acta Odontol Scand* 1993;51:59–64.
- Blatz MB, Sadan A, Kern M. Ceramic restorations. *Compend Contin Educ Dent* 2004;25:306–312.
- Blatz MB. Long-term clinical success of all-ceramic posterior restorations. *Quintessence Int* 2002;33:415–426.
- Sadan A, Blatz MB, Lang B. Clinical considerations for densely sintered alumina and zirconia restorations: Part 1. *Int J Periodontics Restorative Dent* 2005;25:213–219.
- Sadan A, Blatz MB, Lang B. Clinical considerations for densely sintered alumina and zirconia restorations: Part 2. *Int J Periodontics Restorative Dent* 2005;25:343–349.
- Zeng K, Oden A, Rowcliffe D. Flexure tests on dental ceramics. *Int J Prosthodont* 1996;9:434–439.
- Oden A, Andersson M, Krystek-Ondracek I, Magnusson D. Five-year clinical evaluation of Procera AllCeram crowns. *J Prosthet Dent* 1998;80:450–456.
- Odman P, Andersson B. Procera AllCeram crowns followed for 5 to 10.5 years: A prospective clinical study. *Int J Prosthodont* 2001;14:504–509.
- Fradeani M, D'Amelio M, Redemagni M, Corrado M. Five-year follow-up with Procera all-ceramic crowns. *Quintessence Int* 2005;36:105–113.
- Galindo ML, Hagmann E, Marinello CP, Zitzmann NU. Long-term clinical results with Procera AllCeram full-ceramic crowns. *Schweiz Monatsschr Zahnmed* 2006;116:804–809.
- Gamborena I, Blatz MB. A clinical guide to predictable esthetics with zirconium oxide ceramic restorations. *Quintessence Dent Technol* 2006;29:11–23.
- Holst S, Bergler M, Steger E, Blatz MB, Wichmann M. The application of zirconium oxide frameworks for implant superstructures. *Quintessence Dent Technol* 2006;29:103–112.
- Fischer H, Weber M, Marx R. Lifetime prediction of all-ceramic bridges by computational methods. *J Dent Res* 2003;82:238–242.
- Aboushelib MN, de Jager N, Kleverlaan CJ, Feilzer AJ. Effect of loading method on the fracture mechanics of two layered all-ceramic restorative systems. *Dent Mater* 2006;18(Epub ahead of print).
- Blatz MB, Chapman L, Chiche GJ, Mercante D. Shear bond strength of veneering ceramics to zirconium-oxide ceramic [abstract 0888]. *J Dent Res* 2006;85(special issue A).
- Burke FJ, Fleming GJ, Nathanson D, Amrquis PM. Are adhesive technologies needed to support ceramics? An assessment of the current evidence. *J Adhes Dent* 2002;4:7–22.
- Blatz MB, Sadan A, Kern M. Resin-ceramic bonding—A review of the literature. *J Prosthet Dent* 2003;89:268–274.
- Blatz MB, Sadan A, Kern M. Adhesive cementation of high-strength ceramic restorations: Clinical and laboratory guidelines. *Quintessence Dent Technol* 2003;26:47–55.
- Oppes S, Blatz MB, Sadan A, Chiche G, Kee E, Mercante DE. Influence of cement on microleakage and strength of ceramic crowns [abstract 2090]. *J Dent Res* 2006;85(special issue B).
- Okutan M, Heydecke G, Butz F, Strub JR. Fracture load and marginal fit of shrinkage-free ZrSiO<sub>4</sub> all-ceramic crowns after chewing simulation. *J Oral Rehabil* 2006;33:827–832.
- Bindl A, Luthy H, Mormann WH. Thin-wall ceramic CAD/CAM crown copings: Strength and fracture pattern. *J Oral Rehabil* 2006;33:520–528.
- Yildirim M, Edelhoff D, Hanish O, Spiekermann H. Ceramic abutments—A new era in achieving optimal esthetics in implant dentistry. *Int J Periodontics Restorative Dent* 2000;20:81–91.
- Glauser R, Sailer I, Wohlwend A, Studer S, Schibli M, Schärer P. Experimental zirconia abutments for implant-supported single-tooth restorations in esthetically demanding regions: 4-year results of a prospective clinical study. *Int J Prosthodont* 2004;17:285–290.
- Glauser R, Wohlwend A, Studer S. Application of zirconia abutments on single-tooth implants in the maxillary esthetic zone. A 6-year clinical and radiographic follow-up report. *Appl Osseointegration Res* 2004;4:41–45.
- Yildirim M, Fischer H, Marx R, Edelhoff D. In vitro fracture resistance of implant-supported all-ceramic restorations. *J Prosthet Dent* 2003;90:325–331.

26. Att W, Kurun S, Gerds T, Strub JR. Fracture resistance of single-tooth implant-supported all-ceramic restorations after exposure to the artificial mouth. *J Oral Rehabil* 2006;33:380–386.
27. Att W, Kurun S, Gerds T, Strub JR. Fracture resistance of single-tooth implant-supported all-ceramic restorations: An in vitro study. *J Prosthet Dent* 2006;95:111–116.
28. Studart AR, Filser F, Kocher P, Gauckler LJ. Fatigue of zirconia under cyclic loading in water and its implications for the design of dental bridges. *Dent Mater* 2006;10(Epub ahead of print).
29. Sailer I, Feher A, Filser F, Luthy H, Gauckler LJ, Scharer P, Franz Hammerle CH. Prospective clinical study of zirconia posterior fixed partial dentures: 3-year follow-up. *Quintessence Int* 2006;37:685–693.