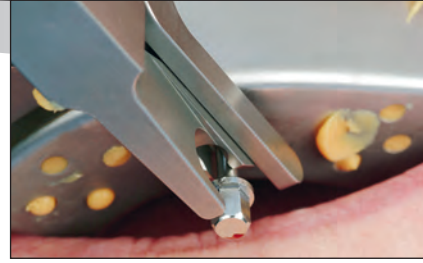


CURRENT CLINICAL AND TECHNICAL PROTOCOLS FOR SINGLE-TOOTH IMMEDIATE IMPLANT PROCEDURES



Iñaki Gamborena, DMD, MSD, FID¹
Markus B. Blatz, DMD, PhD²

Loss of a single tooth and its replacement with an implant-supported restoration in the esthetic zone present several challenges when optimal function and esthetics are the goals.¹⁻³ Immediate placement of dental implants into fresh extraction sockets limits overall treatment time and offers some esthetic and functional advantages.⁴ A recent systematic review of the scientific evidence supports immediate implant placement as a safe procedure when certain guidelines are followed.⁵ Immediate provisionalization or restoration of such implants provides additional benefits to the pa-

tient in terms of appearance, chewing ability, and overall length of treatment.⁴ A provisional removable appliance in the form of a denture or retainer is avoided.⁴ The existing evidence supports the immediate restoration of dental implants after insertion and reports clinical success rates comparable to traditional multistep protocols.⁶ Numerous publications have reported excellent success with these treatment options and discussed diagnostic, surgical, and technical parameters more or less independently from each other.

This article presents a comprehensive approach to optimize functional and esthetic results with immediate implant placement and immediate restoration by blending surgical, technical, and restorative steps into one successful protocol.

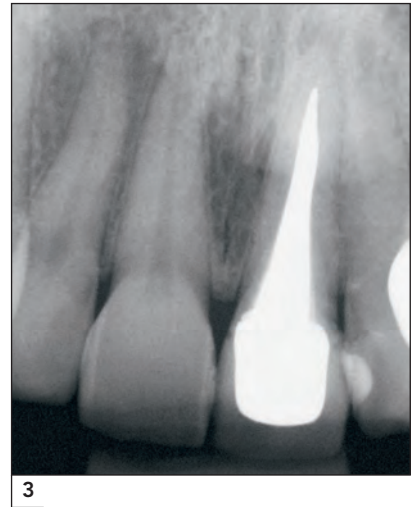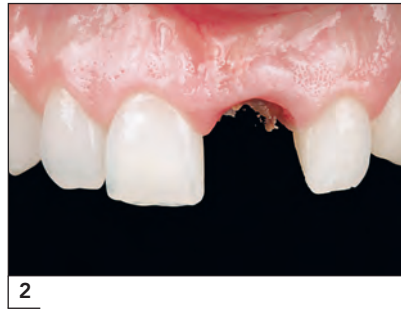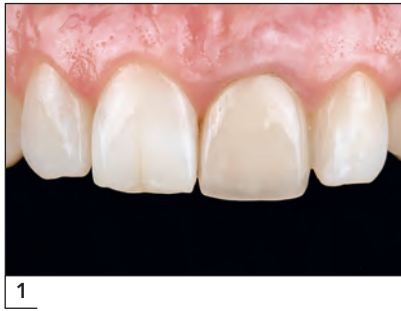¹Clinical Assistant Professor, Department of Preventive and Restorative Sciences, University of Pennsylvania School of Dental Medicine, Philadelphia, Pennsylvania, USA; Private Practice, San Sebastian, Spain.

²Professor of Restorative Dentistry and Chairman, Department of Preventive and Restorative Sciences, University of Pennsylvania School of Dental Medicine, Philadelphia, Pennsylvania, USA.

Correspondence to: Dr Iñaki Gamborena, Resurreccion m^a de azkue, 6 20018 San Sebastian, Spain.
E-mail: gambmila@telefonica.net

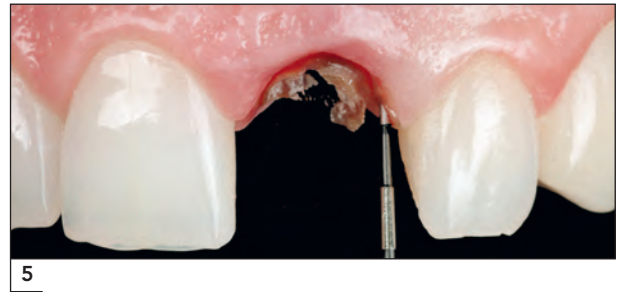
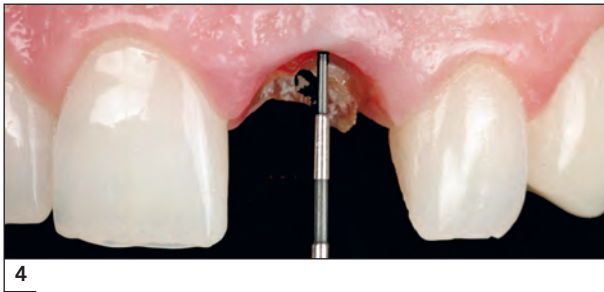
CASE SELECTION

The driving philosophy behind current implant/restorative protocols is *preservation*. The preservation of existing and intact oral structures



Figs 1 to 3 Initial situation with a failing maxillary left central incisor in a 44-year-old patient.

Figs 4 and 5 Buccal and interproximal bone sounding.



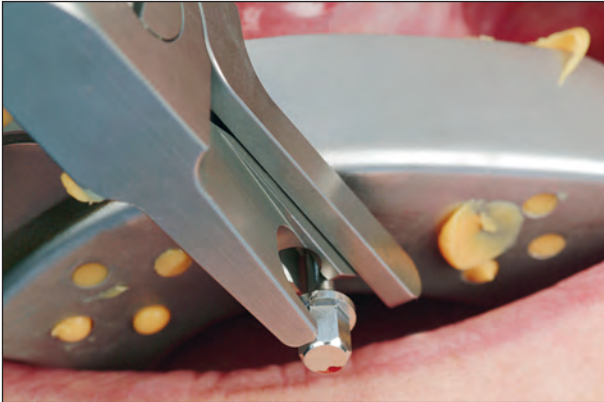
requires a sensitive and conservative treatment approach. Careful case selection and comprehensive treatment planning are essential for final success. The following parameters must be present in each tooth for optimal clinical success with immediate implant placement:

1. Normal dentogingival complex (3 mm from the free gingival margin to the bone crest on the buccal aspect and 4.5 mm interproximally)
2. Tooth position centered with the buccolingual bone plates and normal orientation within the arch
3. Medium to thick gingival biotype

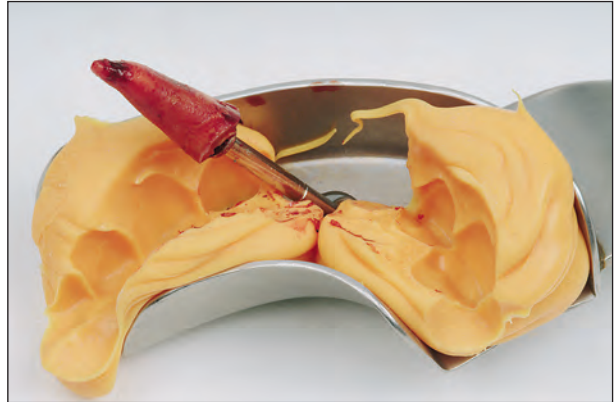Figures 1 to 3 show the initial intraoral situation of a 44-year-old patient with a failing maxillary left central incisor. The parameters above were verified preoperatively via thorough examination and bone sounding (Figs 4 and 5).

SURGICAL PROTOCOL

Atraumatic tooth extraction is the first and one of the most critical steps of immediate implant placement. Even small periostomes—typically forced between the alveolar bone and the root of the tooth—may damage vital structures and compromise healing. One recommended technique for atraumatic extraction is to hollow out the tooth with rotating instruments and remove remaining tooth fragments from the inside. Commercial products such as the Easy X-TRAC system (ATitan Instruments, Hamburg, NY) allow for atraumatic extraction without damaging instruments and rotary movements, minimize loss of bone and soft tissue, reduce posttraumatic swelling, and provide excellent conditions for immediate implant placement (Figs 6 and 7). Preparation of the implant bed (osteotomy) with the recommended sequence of bone drills should



6

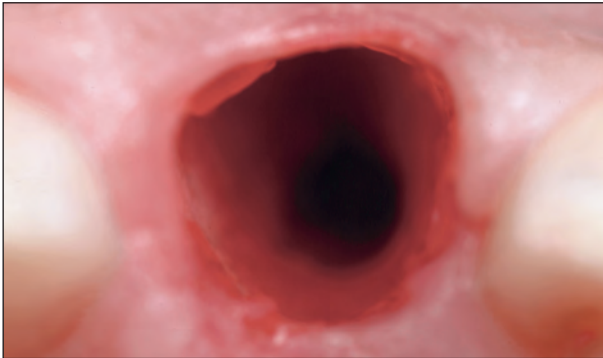


7

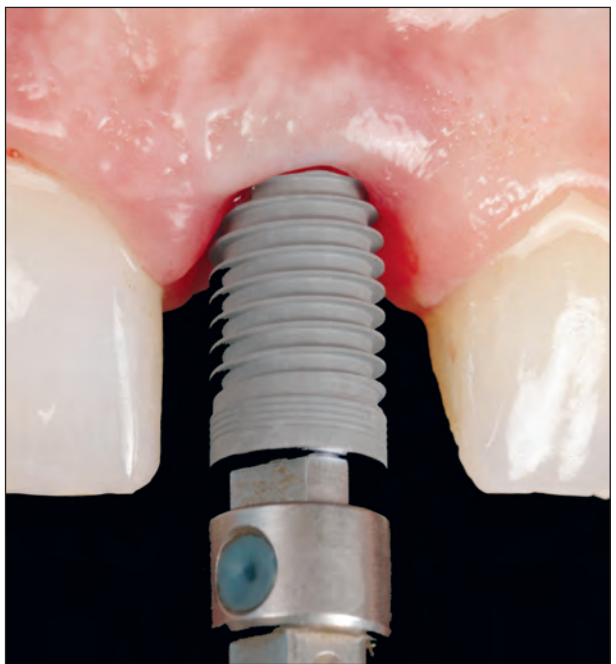
Figs 6 and 7 Atraumatic tooth extraction using the Easy X-TRAC system.

Fig 8 Palatal osteotomy for optimal implant positioning and angulation.

Fig 9 A tapered dental implant is placed immediately after tooth extraction with a flapless surgical procedure.



8



9

start on the palatal aspect of the extraction socket when an anterior tooth is immediately replaced. It is a common error to start the osteotomy with the bur centered in the alveolus. During drilling, the bur is typically displaced toward the less resistant bony wall, which, in most cases, is the buccal wall. Such displacement causes the implant to be either positioned too far buccally or angulated unfavorably, which makes final restoration more difficult and sometimes even impossible. For an ideal osteotomy, the

drills should be placed along the palatal wall of the extraction socket to achieve a final implant location centered between the incisal edge and cingulum of the prospective tooth. The diameter of the selected implant should be as close as possible to the cervical alveolar diameter of the extracted root. Figure 8 shows the palatal osteotomy in the present case. A NobelReplace Select Tapered Groovy implant (5 × 13 mm, Nobel Biocare, Göteborg, Sweden) was placed in the extraction socket of the central incisor (Fig 9). A

bone substitute material (eg, Bio-Oss, Osteohealth, Shirley, NY) may be placed in the gaps between the implant and alveolar bone to avoid resorption. Condensation of the bone filling material can be simplified by attaching a narrower healing abutment to the implant, for example, by attaching a regular-platform abutment to a wide-platform implant. This increases visibility and ensures that bone filling particles are not trapped in the implant-abutment connection.

It was planned to connect a definitive prefabricated abutment to the implant immediately after surgery. In such cases, it is key to ensure proper orientation of the implant and its connection interface to facilitate correct orientation of the prefabricated abutment and provisional restoration. The trilobe connection and indicator marks of the NobelReplace Select implant provide simple references; one of the lobes should be oriented toward the buccal aspect. This configuration allows some prosthetic components to be prepared preoperatively and transferred easily to the patient's mouth.

RESTORATIVE PROTOCOL

It is recommended to insert the final implant abutment as soon as possible after implant placement, preferably on the same day. This will avoid repetitive mutilation of the fragile peri-implant soft tissue collar, which occurs whenever abutments are removed or inserted. Abutment disconnections and reconnections compromise the mucosal barrier and result in a more "apically" positioned zone of connective tissue, thus leading to marginal bone resorption.¹⁰


Implant abutments made from zirconium oxide ceramic provide sufficient strength, excellent biologic response, and superior esthetic properties.^{7,8} The white color of zirconia ceramic abutments prevents grayish discoloration of peri-implant soft tissues. It is also beneficial in the event of postoperative soft tissue recession, which seems unavoidable in immediate implant protocols.⁹ A

metal alloy abutment would possibly be exposed and severely compromise the esthetic outcome of the restoration. Two aspects that may limit the amount of bone and soft tissue recessions are delicate atraumatic handling during all clinical procedures (eg, avoiding dis- and reconnections of implant abutments) and a thick tissue biotype.

Prefabricated Zirconia Abutments

For the aforementioned reasons, a customized definitive zirconia abutment that does not need to be removed again should be inserted immediately after implant placement. One option is to scan and fabricate a customized abutment (eg, Procera Zirconia Abutment, Nobel Biocare) before the surgery based on the diagnostic waxup. Another option is to insert and customize a prefabricated abutment at the time of surgery. The NobelReplace Procera Esthetic Abutment Kit (Nobel Biocare) includes an assortment of prefabricated zirconia abutments that can be selected, inserted, and prepared chairside. The prefabricated zirconia abutments feature a removable internal implant connection (NobelReplace Select). The selection kit is organized by the size of the implant connection as narrow platform (NP), regular platform (RP), and wide platform (WP). The abutments are available in various diameters, finish-line heights, and angulations. Abutment designs and dimensions were developed based on average values from the Procera software network. Finish-line heights range from 1.5 to 2 mm. Since the implant should ideally be placed about 3 mm below the free gingival margin, the abutment with the 2-mm finish-line height is often used for chairside preparation. Abutment selection is simplified by measuring the mesiodistal width of the original root in the preoperative periapical radiograph. The measurement should be taken at the most coronal part of the portion of the root that is left within the dentogingival complex. The abutment should support the surrounding tissue and clinical crown in the transmucosal area in the same manner as the natural tooth.

Fig 10 Platform-shifting adapters for the Replace Select trilobe internal connections were used to convert RP implants to NP abutments (*right*) and WP implants to RP abutments (*left*).



10

Platform Shifting

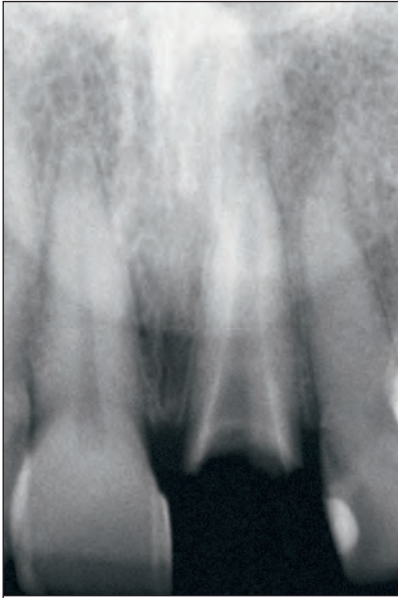
There is increasing evidence that supports the concept of platform switching. This concept refers to the connection of restorative components with smaller diameters to implant platforms with larger diameters. The positive effects of platform switching were discovered by coincidence when an implant manufacturer introduced wide-diameter implants.¹¹ Initially, prosthetic abutments with matching diameters were not available; therefore, smaller-diameter abutments were used, causing circumferential horizontal discrepancies. When radiographs of these restorations were taken and examined 5 years postoperatively, the crestal bone lateral to the implants appeared to respond differently from what is typically observed with same-sized implant-abutment components: There was significantly less crestal bone loss.¹² The authors concluded that this was caused by the inward shift of the implant-abutment junction. The inflammatory cell infiltrate was repositioned and confined within a 90-degree area that was not directly adjacent to the crestal bone. In addition, a biomechanical analysis by Maeda et al¹³ demonstrated a shift of the stress concentration area away from the cervical bone/implant interface. In a recent prospective clinical trial, Huerzeler et al¹⁴ found that platform-switched abutments caused significantly less crestal bone resorption. These and other authors reason that the reduced crestal bone loss has a positive effect on the peri-implant soft tissue and, ultimately, the esthetic outcome.¹⁴⁻¹⁶ Esthetic predictability makes platform switching a preferred

concept for immediate placement/restoration protocols. However, although the existing evidence is encouraging, more clinical data with various implant systems are needed.

Platform switching may be performed simply by using prosthetic components that have smaller diameters at the connection interface than the supporting implants, provided that the connecting interfaces have the same dimensions. Otherwise, special components such as the recently introduced platform-shifting adapters (Nobel Biocare) must be used. These platforming-shifting adapters are designed for Replace Select trilobe internal connections and convert RP and WP implants to NP and RP abutments, respectively (Fig 10). At the same time, they switch internal connection (trilobe) implants to external hex platforms.

Chairside Abutment Selection and Preparation

When measured on the preoperative radiograph (Fig 11), the mesiodistal width of the failing root was 6.6 mm. An RP abutment with a width of 6.7 mm and a 2-mm finish-line height was selected from the NobelReplace Procera Esthetic Abutment Kit (Figs 12 and 13). The original connection was removed from the zirconia abutment. The adapter that converts WP implants to RP abutments was attached to the abutment and both were screwed onto the WP implant (NobelReplace Tapered Groovy). Care was taken to orient and align the

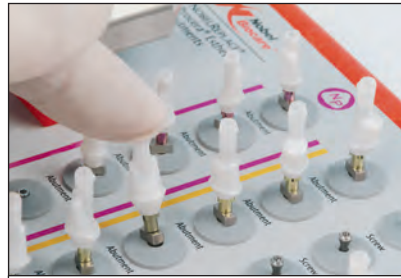

11

Fig 11 Mesiodistal width of coronal aspect of the root was measured on the preoperative periapical radiograph to select the abutment with the closest diameter.

Fig 12 Prefabricated zirconia abutment kit offers various diameters, angulations, and finish-line heights.

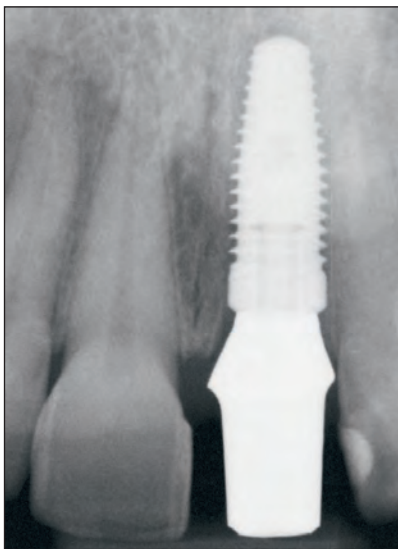
Fig 13 Chairside selection of a prefabricated zirconia abutment with the same diameter as the extracted tooth.



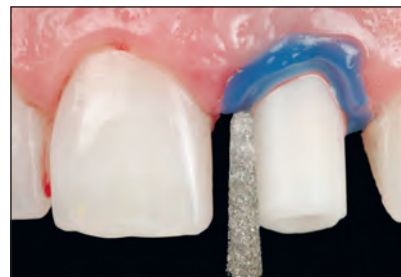12



13



14



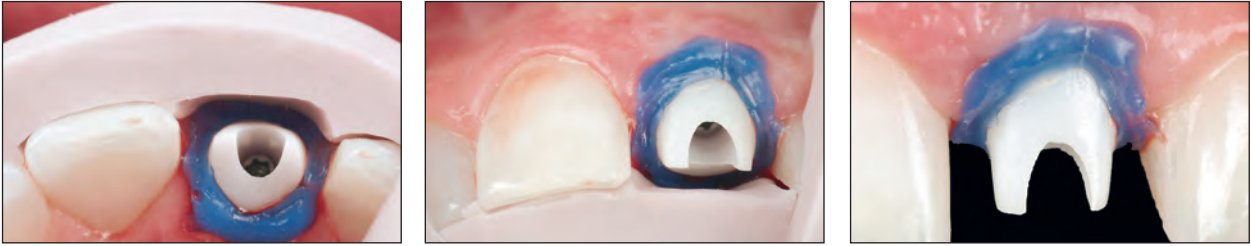
15

Fig 14 Radiograph used to verify fit and proper seating of the prefabricated zirconia abutment.

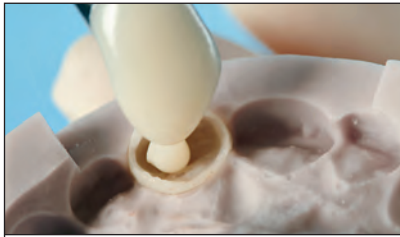Fig 15 Intraoral preparation of the prefabricated zirconia abutment. Block-out material is used to avoid penetration of zirconia particles into the gap between the abutment and free gingival margin.

connection and abutment so that the buccal aspect of the abutment coincided with one of the lobes of the implant connection. Proper adaptation was verified with a periapical radiograph (Fig 14). The radiopacity of the zirconia abutment allows for evaluation of the crestal bone and its proximity to the diverging abutment for adequate preparation. After verification of proper seating, three silicone matrices (Zetalabor laboratory high-precision condensation silicone, Zhermack, Badia Polesine, Italy) made from a diagnostic waxup

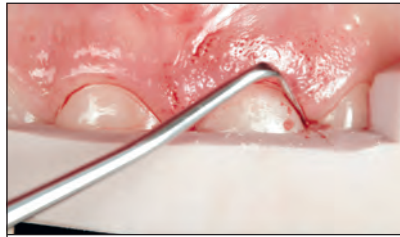
were used for anatomic abutment modifications and provisional shell orientation. The abutment was prepared with diamond burs at a high speed with copious water. A light-curing resin barrier was applied to seal the gap between the free gingival margin and zirconia abutment and to avoid penetration of zirconia particles into the fresh extraction socket during preparation (Fig 15). Final preparation was verified with the silicone indices (Figs 16 to 18) to ensure adequate space for the final restoration. The screw access hole in the abutment



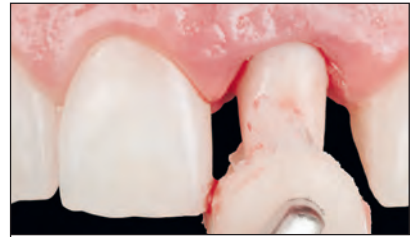Figs 16 to 18 Silicone matrix of the diagnostic waxup used to verify an adequate preparation. This ensures adequate space for the definitive restoration.



19



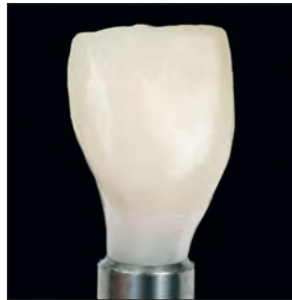20



21



22a



22b



22c



22d

Figs 19 to 21 The provisional crown was prefabricated in the laboratory with a silicone matrix of the diagnostic waxup. The crown is then relined chairside with self-curing acrylic resin and a silicone matrix to ensure exact positioning.

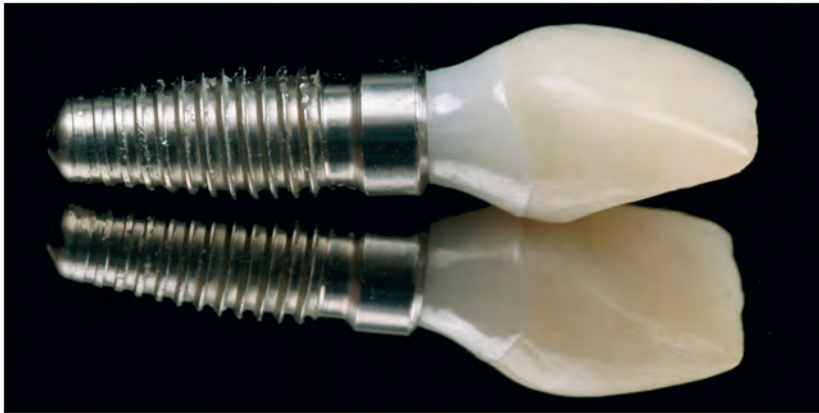
Figs 22a to 22d Anterior and buccolingual views of the provisional crown before (*a and c*) and after (*b and d*) recontouring. Note the subgingival concavity for improved tissue proliferation. Only minor adjustments were necessary, indicating an optimal implant position.

was sealed with Fermit (Ivoclar Vivadent, Amherst, NY), and a separating agent (petroleum jelly) was applied to the abutment.

Provisional Restoration

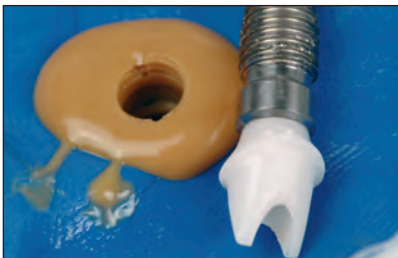It is recommended to fabricate the provisional restoration from the diagnostic waxup before the surgical appointment to simplify the clinical procedure and limit chairside treatment time. The silicone matrix ensured that the provisional crown was properly oriented. The crown was hollowed out

and relined (Figs 19 and 20) with a self-curing acrylic material (Temporary Bridge Resin, Dentsply Caulk, Milford, Delaware). Excess acrylic resin was carefully removed (Fig 21) to maintain the desired emergence profile. The provisional crown and abutment were removed from the implant after complete setting of the acrylic resin and connected to a laboratory analog for finishing and polishing. Excess acrylic resin flashes were trimmed carefully to preserve the original shape and emergence profile. Only minimal adjustments were necessary in this case, indicating optimal implant placement and location (Figs 22a to 22d). A separating agent was



23

Fig 23 Finalized provisional crown. Note the platform shift and subgingival concavity with increasing diameter toward the coronal aspect of the abutment to full contour at the transmucosal level.



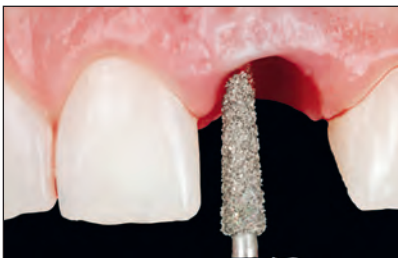24

Fig 24 Final impression of the customized prefabricated abutment for fabrication of the definitive crown.



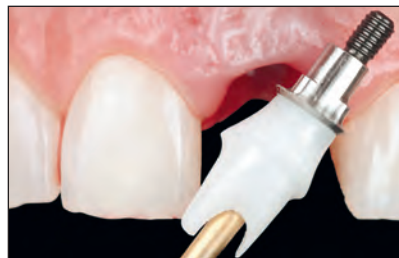25

Fig 25 The abutment was disinfected in 2% glutaraldehyde for 5 minutes before final insertion.



26

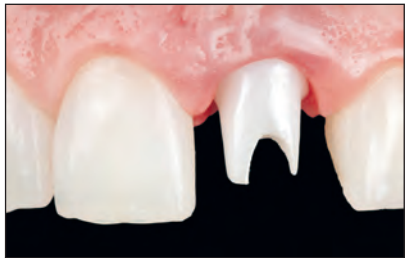Fig 26 Refreshing the sulcular epithelium with a diamond bur before abutment connection.



27

Fig 27 Platform shift adapter and zirconia abutment.

Fig 28 Zirconia abutment in place, demonstrating adequate tissue support.



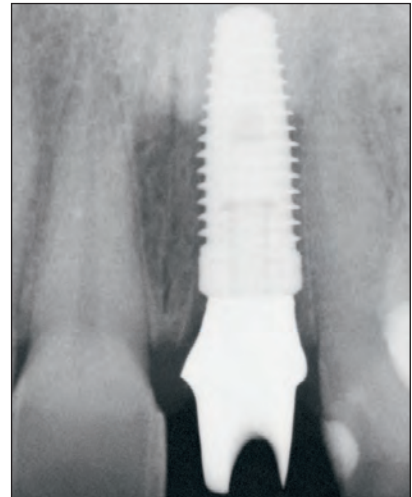
28

again applied to the abutment, and small remaining gaps were filled with acrylic resin to optimize the emergence profile and create a smooth transition between the abutment and provisional crown. Complete curing of the acrylic resin was ensured by placing the relined crown in a pressure pot with hot water for 5 minutes. Silicone diamond disks and water/pumice slurry were used for final polishing (Fig 23). The customized prefabricated zirconia abutment was also highly polished with silicone diamond disks and pumice to minimize bacterial colonization.¹⁷ A final impression was made from the abutment before returning it to the mouth (Fig 24). This impression is necessary for fabrication of the definitive restoration and eliminates the need for future disconnection of the abutment from the im-

plant. It also negates the need for a final impression with the abutment in place, which would typically require tissue retraction. The screw access hole was filled with Fermit (Ivoclar Vivadent), and the impression was carried out with the double-mix impression technique (Virtual VPS putty base, regular set and extra light-body fast set, Ivoclar Vivadent). All prosthetic parts in contact with tissues were placed in a glutaraldehyde solution of 2% for 5 minutes for disinfection (Fig 25). The sulcular epithelium was refreshed with a diamond bur (Fig 26). Figure 27 depicts the WP-RP platform-shifting adapter connected to the abutment. The abutment was screwed on the implant with a torque of 35 Ncm and thoroughly rinsed with water (Fig 28). The provisional restoration was then cemented with

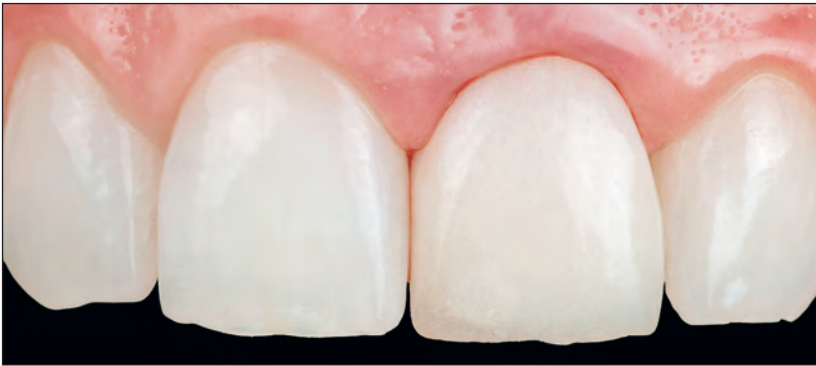

Fig 29 Postoperative labial view of the immediate provisional crown supported by the prefabricated zirconia abutment and immediately placed implant at the left central incisor site.

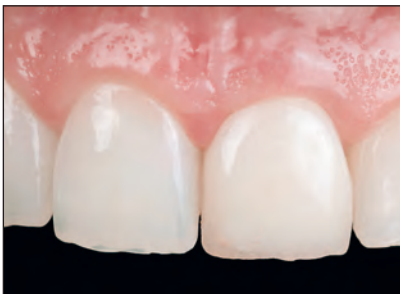

30

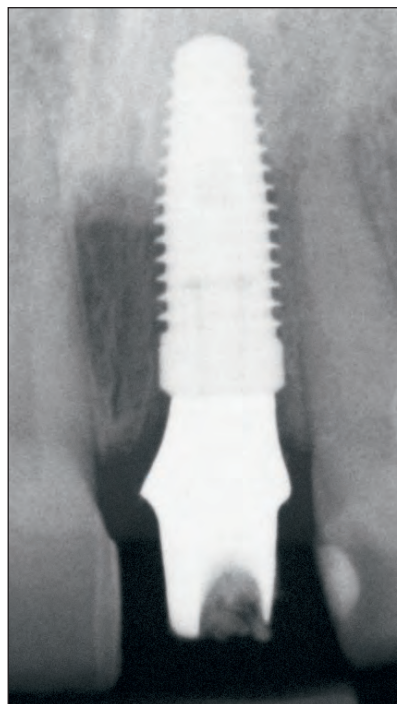
Fig 30 Postoperative radiograph. Note the level of crestal bone.

Figs 31 to 33 Intraoral and radiographic views 6 months after surgery. The abutment placed at the time of surgery is not removed in order to avoid disturbance of the fragile peri-implant soft tissue.

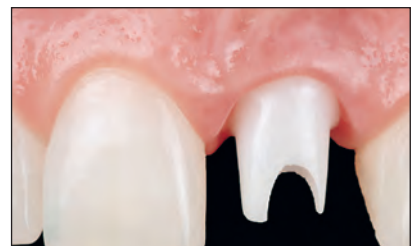Figs 34a and 34b Occlusal views of the preoperative (a) and 6-month postoperative (b) situation. The customized prefabricated zirconia abutment provides adequate tissue support.



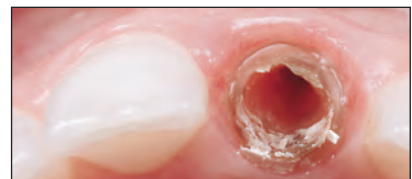31



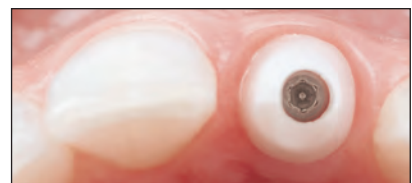32



33



34a

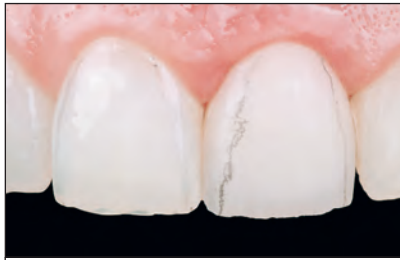


34b

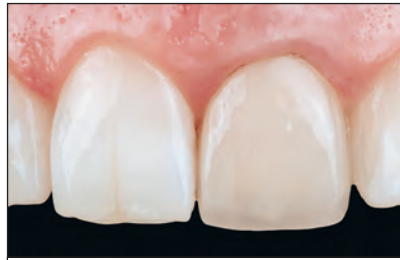temporary cement (Temp-bond NE, Kerr, Orange, California, USA). The cement was applied with a thin brush to minimize excess. Functional and esthetic parameters were verified after removal of excess cement (Fig 29) and radiographic examination (Fig 30). The absence of occlusal contacts on the provisional crown during excursions was verified with articulating film. Follow-up visits were scheduled for 15 days, 1 month, 2 months, 3 months, and 6 months later.

Final Restoration

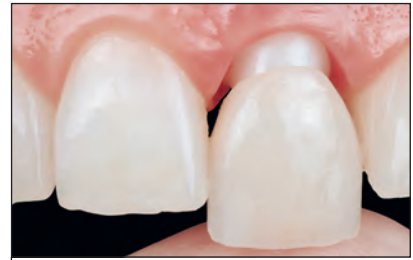All relevant parameters were re-evaluated 6 months after implant placement and provisionalization. Wound healing and soft tissue integration were ideal, and radiographic evaluation revealed positive bone remodeling (Figs 31 to 33). Figures 34a and 34b provide a comparison of tissue support between the original situation and the prepared Procera Esthetic abutment (Nobel Biocare).



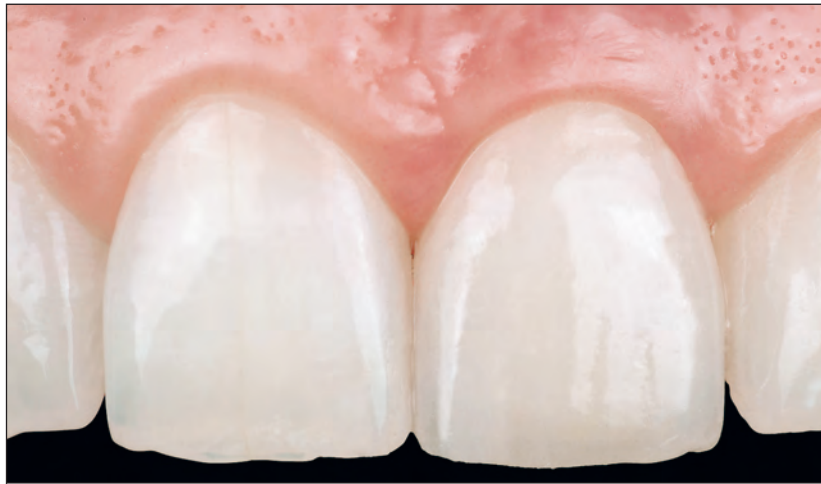35



36a



36b



36c

Fig 35 Try-in of definitive crown at the bisque-bake stage.

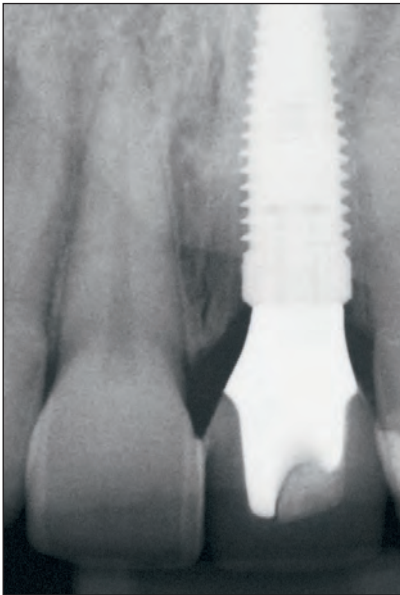
Figs 36a to 36c Labial views of the initial situation (a) and try-in (b) and cementation (c) of the definitive crown.

A master cast was fabricated from the impression of the abutment and scanned with the Procera Forte scanner (Nobel Biocare) for the fabrication of a 0.4-mm Procera Alumina coping (Nobel Biocare). A pick-up impression was made with the double-mix technique (Virtual VPS putty base, regular set and extra light-body fast set) to finalize the Procera Alumina Crown. The 0.4-mm translucent coping was preheated to 1,000°C for 15 minutes to create a whitish appearance. Conventional porcelain layering techniques were then applied to finalize shape and color. These parameters, the interproximal contacts, and the occlusion were verified and adjusted at the bisque-bake try-in (Fig 35). The dramatic esthetic improvement from the initial situation to try-in and final insertion of the definitive restoration is shown in Figs 36a to 36c. Final cementation was performed with adhesive resin (RelyX Unicem transparent, 3M ESPE, St Paul, MN). Ultimate fit, osseous implant integration, and bone support were verified with a periapical radiograph (Fig 37). The intraoral initial situ-

ation compared to the final result is shown in Figs 38a and 38b. A follow-up evaluation 2 years post-operatively revealed stable conditions (Figs 39 and 40). Figure 41 demonstrates the esthetic integration of the definitive restoration in the patient's smile.

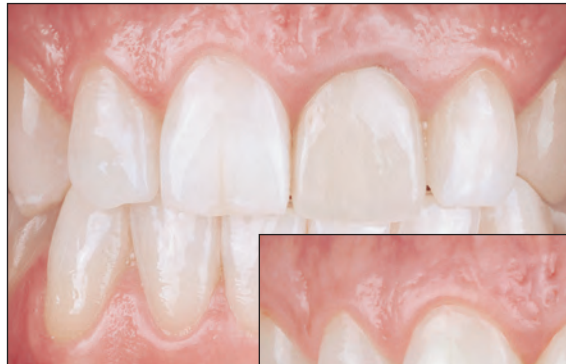CONCLUSION

Immediate surgical and restorative protocols facilitate superior esthetic and functional success. However, strict guidelines for atraumatic intervention and preservation of existing anatomic structures must be carefully followed. This article presented a comprehensive treatment approach and discussed current immediate procedures based on the existing scientific evidence. The sequential surgical, technical, and restorative techniques were blended into one successful protocol, which was demonstrated with a clinical case report.

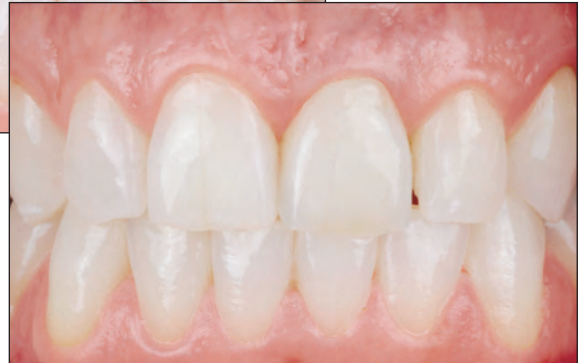

37

Fig 37 Radiograph of the definitive crown after cementation. Note the crestal bone level.



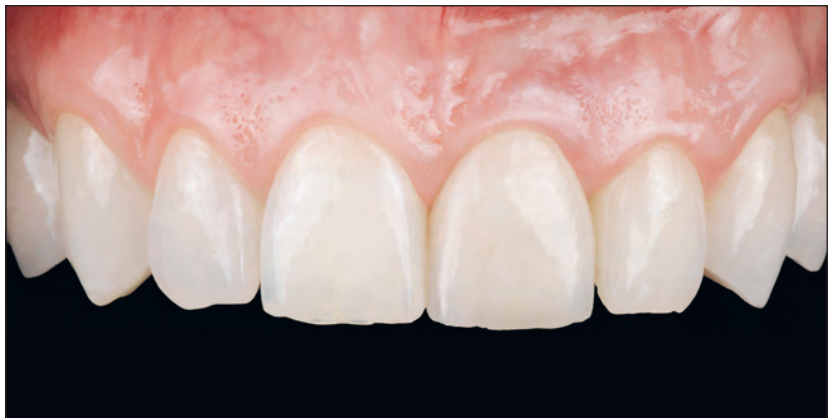38a



38b

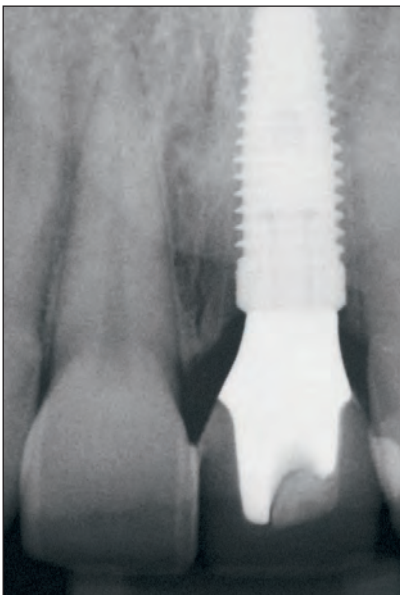
Figs 38a and 38b Labial views of the preoperative (a) and postoperative (b) situation.

Figs 39 and 40 Two-year postoperative intraoral and radiographic situation.

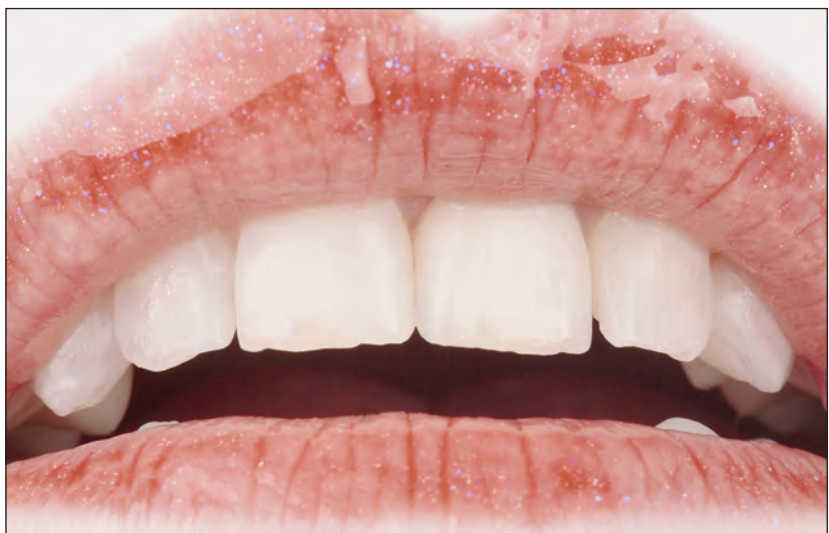

39

Fig 41 Final extraoral view showing excellent esthetic integration.



40



41

ACKNOWLEDGMENT

The authors thank Mr Iñigo Casares for the beautiful porcelain work featured in the case presentation.

REFERENCES

- Gamborena I, Blatz MB. Transferring the emergence profile of single-tooth implant restorations. *Quintessence Dent Technol* 2004;27:119–132.
- Sadan A, Blatz MB, Salinas TJ, Block M. Single-implant restorations: A contemporary approach for achieving a predictable outcome. *J Oral Maxillofac Surg* 2004;62:73–81.
- Sadan A, Blatz MB, Bellerino M, Block M. Prosthetic design considerations for anterior single-implant restorations. *J Esthet Restor Dent* 2004;16:165–175.
- Barone A, Rispoli L, Voza I, Quaranta A, Covani U. Immediate restoration of single implants placed immediately after tooth extraction. *J Periodontol* 2006;77:1914–1920.
- Esposito MA, Koukouloupoulou A, Coulthard P, Worthington HV. Interventions for replacing missing teeth: Dental implants in fresh extraction sockets (immediate, immediate-delayed and delayed implants). *Cochrane Database Syst Rev* 2006;18:CD005968.
- Esposito M, Grusovin MG, Willings M, Coulthard P, Worthington HV. Interventions for replacing missing teeth: Different times for loading dental implants. *Cochrane Database Syst Rev* 2007;18:CD003878.
- Glauser R, Sailer I, Wohlwend A, Studer S, Schibli M, Schäfer P. Experimental zirconia abutments for implant-supported single-tooth restorations in esthetically demanding regions: 4-year results of a prospective clinical study. *Int J Prosthodont* 2004;17:285–290.
- Jung RE, Sailer I, Hämmerle CH, Attin T, Schmidlin P. In vitro color changes of soft tissues caused by restorative materials. *Int J Periodontics Restorative Dent* 2007;27:251–257.
- Grunder U, Gracis S, Capelli M. Influence of the 3-D bone-to-implant relationship on esthetics. *Int J Periodontics Restorative Dent* 2005;25:113–119.
- Abrahamsson I, Berglundh T, Lindhe J. The mucosal barrier following abutment dis/reconnection. An experimental study in dogs. *J Clin Periodontol* 1997;24:568–572.
- Blatz MB, Strub JR, Gläser R, Gebhardt W. Use of wide-diameter and standard-diameter implants to replace molars: Two case presentations. *Int J Prosthodont* 1998;11:356–363.
- Lazzara RJ, Porter SS. Platform switching: A new concept in implant dentistry for controlling postrestorative crestal bone levels. *Int J Periodontics Restorative Dent* 2006;26:9–17.
- Maeda Y, Miura J, Taki I, Sogo M. Biomechanical analysis on platform switching: Is there any biomechanical rationale? *Clin Oral Implants Res* 2007;18:581–584.
- Huerzeler M, Fickl S, Zühr O, Wachtel HC. Peri-implant bone level around implants with platform-switched abutments: Preliminary data from a prospective study. *J Oral Maxillofac Surg* 2007;65:33–39.
- Baumgarten H, Cochetto R, Testori T, Meltzer A, Porter S. A new implant design for crestal bone preservation: Initial observations and case report. *Pract Proced Aesthet Dent* 2005;17:735–740.
- Gardner DM. Platform switching as a means to achieving implant esthetics. A case study. *N Y State Dent J* 2005;71:34–37.
- Scotti R, Kantorski KZ, Monaco C, Valandro LF, Ciocca L, Bottino MA. SEM evaluation of in situ early bacterial colonization on a Y-TZP ceramic: A pilot study. *Int J Prosthodont* 2007;20:419–412.